



Histopathology of intestinal tissue from *Capra Hircus* L. caused by genus *Moniezia* (Blanchard 1891)

¹ Jadhav VM, ² Kale MK

¹ Department of Zoology, Dr. PK College, Sangli, Maharashtra, India

² Department of Zoology, PVP College, Patoda, Beed, Maharashtra, India

Abstract

Goats have enormous potential to boost economy of developing countries like India and can be major source of income especially to marginal farmers and landless laborers. The present work deals with histopathological study of intestinal tissue of *Capra hircus* infected with Genus *Moniezia* (Blanchard 1891). It is observed that *Moniezia* sp shortened and flattened villi and create local haemorrhages in the intestinal tissue of *Capra hircus*. The luminal site of the duodenum was found to be depressed like cavity because of *Moniezia* sp.

Keywords: histopathology, *Moniezia*, *Capra hircus*

Introduction

Dairy animals have enormous potential to boost economy of developing countries like India and can be major source of income especially to marginal farmers and landless laborers. However goats are vulnerable to various parasitic diseases that not only undermine their health but also play a role in lowering the overall production (Sanyal 1996) [11] and are responsible for causing heavy losses due to reduced production, morbidity and mortality in animals (Mahusoon *et al.* 2004; Nwosu *et al.* 2007; Torres-Acosta and Hoste, 2008) [6, 10, 14] especially in developing countries. Parasitic infestation are the main problems that affecting productivity and cause great economic losses in farm animals (El-Khadrawy, 2008) [4]. Gastrointestinal parasitism is one of the major health problems severely limiting the productivity of dairy animals in India (Jithendran and Bhat, 1999) [5]. Cestodes are said to absorb semi digested material from the intestine and it has been assumed that these worms lie in a both of semi digested 'soup' from which they can absorb nutrient, metabolism and in vitro studies suggest that a complex nutritional relationship occurs between cestode and its host (Nanware and Bhure, 2013) [9]. The present study reports incidence and some histopathological aspects of genus *Moniezia* in present area of Sangli Dist.

Material and Methods

The sample of infected intestine of *Capra hircus* were collected from slaughter houses from Sangli city. Examination of the tissue was done to find the rate of infection. The main sites observed for parasitic infection were intestine. The study revealed infection of *Capra hircus* by *Moniezia* sp, whose identification was confirmed from morphological features (Solusby 1982 and Yamaguti, 1959) [16]. Some intestines were found to be infected and some are normal. Both infected and normal hosts intestine were dissected and fixed in Bouin's fluid to study histopathological changes. The fixed materials from Bouin's fluid were removed, washed, dehydrated through

alcoholic grades, cleared in xylene and embedded in paraffin wax (58-62°C). The blocks were cut at 9µ and slides were stained in Eosin Haematoxylin double staining method. Best slides or sections were selected and observed under the microscope for histopathological study.

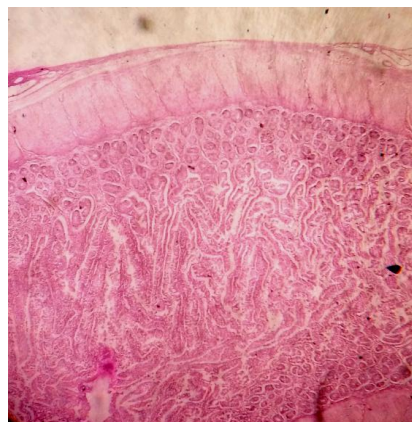


Fig 1: Healthy intestinal villi of *Capra hircus*

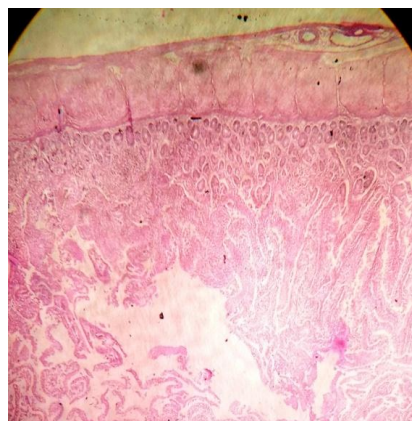


Fig 2: Infected intestinal villi of *Capra hircus*

Result and Discussion

In the present histopathological study, intestine of *Capra hircus* infected with *Moniezia Sp* showed the proliferation of lining epithelial cells with the shortening, flattening and rupture of villi of crypts of liberkuhn and local haemorrhages. There was thickening of mucosa and submucosal layers due to infiltration of mononuclear cells and a few plasma cells. Our histopathological study is in agreement with (Nath and Pande, 1963; Verma, 1966; Amjadi, 1971; Avasthi *et al.*, 1981 and Tegtmeier *et al.*, 2007) [7, 15, 1, 2, 13], who have also reported changes in various tissues of host animals with other cestodes. The present result was also confound by result of Bystrova and Davydov (1966) [3] who recorded partial obliteration of villus structure and superficial necrosis in the intestine of sheep infected with *Moniezia expansa*. Similar finding has been reported by Nanware and Bhure (2011) [8] mucosal layer disintegrated to form granular masses in the intestinal tissue of *Capra hircus* infected with *Stilesia sp*. The damage was severe, resulting in a condition like sessile adenoma, and in some places the mucosal region was thickened, producing a condition like pedunculate adenoma.

Conclusion

Keeping in view the present findings, it can be concluded that there is urgent need for chemotherapeutic and prophylactic strategies for the monieziosis control in Sangali Region

Acknowledgements

The Authors are thankful to Principal, P.V.P. College, Patoda, Dist. Beed and also thankful to the principal, S.M.D.M. College, Kallamb, Dist. Osmanabad for providing the necessary laboratory facilities to carry out this work during the study period.

References

1. Amjadi AR. Studies on histopathology of *Stilesia globipuntata* infection in Iran. *Veterinary Record*, 1971; 88:486-488.
2. Avasthi BL, Varghese K, Heranjal DD. Efficacy of compound of SRC-4402 against poultry cestodes. II. Histopathological observation on treated and untreated birds. *Indian Journal of Poultry Science*, 1981; 16:286-287.
3. Bystrova TA, Davydov AS. Pathological changes in sheep experimentally infected with *Moniezia expansa*. *Vet Bull*, 1966; 38:23-25.
4. El-Khadrawy HH, Faragalla ME, Abd El Aziz MM, Ahmed WM. Field Investigation on the Correlation between Ovarian Activity and Fascioliosis in Buffalo-Cows. *American-Eurasian Journal of Agriculture and Environment. Science*. 2008; 3(4):539-546.
5. Jithendran KP, Bhat TK. Epidemiology of parasites in dairy animals in the North-West Humid Himalayan region of India with particular reference to gastrointestinal nematodes. *Tropical Animal Health and Production*, 1999; 31:205-214.
6. Mahusoon MM, Perera ANF, Perera ERK, Perera KA. Effect of molybdenum supplementation on circulating mineral levels, nematode infection and body weight in goats as related to season. *Trop Agric Res*, 2004; 16:128-136.
7. Nath D, Pande BP. A histopathological study of the lesion in tapeworm infestation of domestic fowl. *Indian Journal of Veterinary Science*, 1963; 33:1-7.
8. Nanware SS, Bhure DB. Histopathology of intestinal tissue of host *Capra hircus* caused by anoplocephalidean Cestode *Stilesia*. *Journal of Experimental Sciences*. 2011; 2(7):38-39.
9. Nanware SS, Bhure DB. Studies on the cestode *stilesia railliet*, 1893 intestinal infection in *Capra hircus* L. with reference to histopathology. *Asian Journal of Bio Science*. 2013; 8(1):76-78.
10. Nwosu CO, Madu PP, Richards WS. Prevalence and seasonal changes in the population of gastrointestinal nematodes of small ruminants in the semi-arid zone of north eastern Nigeria. *Vet Parasitol*. 2007; 144:118-124.
11. Sanyal PK. Gastro-intestinal parasites and small ruminant production in India. In: Lejambre LF, Knox MR eds. sustainable parasite control in small ruminants. *ACIAR Proceeding*, 1996; 74:109-112.
12. Soulsby E.J.L. Helminths, Arthropods and protozoa of Domesticated animals, 7th Edition the English Book society and bailliere Tindall, London, 1982.
13. Tegtmeier PC, Ganter M, Himmelstjerna G, Von S, Ellendorff F. Monieziosis in sheep-a survey of pathogenicity and effectiveness of treatment with Praziquantel. *Tierarztliche Praxis. Ausgabe G, Grosstiere/ Nutztiere*. 2007; 35(3):183-189.
14. Torres-Acosta JFJ, Hoste H. Alternative or improved methods to limit gastrointestinal parasitism in grazing sheep and goats. *Small Rumin*, 2008; 77:159-173.
15. Verma BB. A note on *Hymenolepis* infection in chickens. *Indian Veterinary Journal*, 1966; 43:264-266.
16. Yamaguti S. *Systema Helminthum* Inter Science Publishers, 1959, 1.